Cutaneous Metastases 122

Christine J. Ko and Jennifer M. McNiff

Key features

- Cutaneous metastases are uncommon and rarely may be the presenting sign of an internal malignancy
- In general, cutaneous metastases are associated with a poor prognosis
- In women, breast carcinoma and melanoma are the malignancies that most frequently metastasize to the skin
- In men, melanoma and carcinomas of the head and neck, lung, and colon are the malignancies that most frequently metastasize to the skin
- Among common malignancies, breast carcinoma is the most likely to metastasize to the skin
- The most common clinical presentation for a cutaneous metastasis is a firm, painless, erythematous nodule
- Cutaneous metastases may arise in the anatomic vicinity of the primary cancer
- Cutaneous metastases typically have histologic features similar to, but not necessarily identical to, those of the primary malignancy
- Treatments include excision, chemotherapy, immunotherapy, and radiotherapy; the latter is often administered for palliation

INTRODUCTION

Given their prognostic implications, cutaneous metastases represent an important dermatologic entity. The skin is not a particularly common site for metastatic spread, and because the clinical appearance of cutaneous metastases can mimic more common disorders, e.g. epidermoid cysts (inflamed and non-inflamed; Fig. 122.1), lipomas, cellulitis, there may be a delay in diagnosis. This is especially true when the primary malignancy is occult. An understanding of the clinical spectrum as well as advances in histological assessment of skin metastases is vital to establishing the correct diagnosis.

Fig. 122.1 Cutaneous metastasis of small cell lung carcinoma. A skin-colored nodule on the neck that resembles an epidermoid cyst or lipoma. *Courtesy Ian Odell, MD, PhD.*

EPIDEMIOLOGY

Depending upon the series, cutaneous metastases occur in 1% to 10% of patients with metastatic disease (to any organ)[1]. Although uncommon, their recognition is important because they can be the first sign of metastatic disease and, as a result, have profound prognostic implications. The proportion of patients with metastatic disease who have cutaneous metastases depends upon the particular malignancy, e.g. the highest incidence is in individuals with metastatic melanoma, where up to 45% of patients can develop skin metastases (Table 122.1)[1]. Sex-specific cancer rates also influence the frequency of the various types of cutaneous metastases. In women, skin metastases are most often due to breast carcinoma (70%) and melanoma (12%), followed by carcinomas originating from the ovary, head and neck, and lung[1]. In men with skin metastases, the most common underlying malignancies are melanoma (32%), followed by carcinomas of the head and neck (16%), lung (12%), and colon (11%).

The overall prevalence of a cancer is also an important determinant. For instance, although skin metastases develop in only 2.5% of patients with metastatic lung cancer, they account for 12% of all cutaneous metastases in men due to the high prevalence of lung cancer[1] (Fig. 122.2).

CUTANEOUS METASTASES IN PATIENTS WITH METASTATIC CANCER		
Primary malignancy	**Percentage of all patients with cutaneous metastases***	**Percentage of all patients *with metastatic disease* who developed cutaneous metastases***
Breast	50	30
Melanoma	18	45
SCC (head and neck)†	7	13
Lung	5	2.5
Unknown	4.5	7.5
Colon/rectum	4	4.5
Ovary	2.5	4
Urinary bladder	1.5	8
Endocrine glands	1	12.5
Esophagus	1	8.5
Gallbladder/bile ducts	<1	5.5
Liver	<1	5
Kidney	<1	4.5
Stomach	<1	2
Pancreas	<1	2
Uterine cervix	<1	1
Prostate	<1	<1
Testes	<1	<1

*The percentages are for men and women combined.
†Larynx, oropharynx, nasal sinuses.

Table 122.1 Cutaneous metastases in patients with metastatic cancer. Rates of metastatic spread do vary depending upon the series. *Adapted from Lookingbill DP, Spangler N, Helm KF. Cutaneous metastases in patients with metastatic carcinoma: a retrospective study of 4020 patients. J Am Acad Dermatol 1993;29:228–36.*

Downloaded for Anonymous User (n/a) at Egyptian Knowledge Bank from ClinicalKey.com by Elsevier on March 10, 2024. For personal use only. No other uses without permission. Copyright ©2024. Elsevier Inc. All rights reserved.

Similarly, the age of the patient plays a role, with rhabdomyosarcoma and neuroblastoma responsible for the majority of cutaneous metastases seen in children[2,3].

Cutaneous metastases develop an average of 36 months (range, 1 to 177 months) after the initial diagnosis of the primary malignancy[2,4]. Unfortunately, the vast majority (~95%) of patients with cutaneous metastases have advanced, stage III or IV disease. Rarely, cutaneous metastases can be the presenting sign of an internal malignancy (<1% of all new cancer diagnoses).

PATHOGENESIS

In 1889, Dr Stephen Paget espoused the "seed and soil" hypothesis as the paradigm of metastatic disease – a malignancy must develop the capability to dissociate from its native environment, survive during transit, and then propagate in a new milieu. This process includes detachment, intravasation, circulation, stasis, extravasation, and finally proliferation[5,6]. It is estimated that ≤0.01% of tumor cells shed into the vasculature form metastatic foci at distant sites[7].

The ability of a malignancy to acquire metastatic potential is thought to occur via one of two mechanisms[8]. In the clonal expansion or linear progression model, selective growth advantages are acquired during the course of tumor development. Over time, subpopulations of cells acquire genetic characteristics that enable them to dissociate and then propagate in distant tissues. In this model, metastatic foci have similar phenotypes and genotypes to the original tumor. Alternatively, in the variant or parallel progression model, rare, highly aggressive stem cell-like clones with high metastatic potential exist within the tumor and can cause dissemination at any point during tumorigenesis.

It is generally accepted that certain cancers tend to metastasize to distinct tissues. The mechanism by which they choose their final destination is related to hemostatic forces and surface protein expression patterns. When tumor emboli lodge in the first vascular bed they encounter, adhesion molecule interactions (e.g. integrins) facilitate extravasation and account for the commonly noted involvement of regional nodal basins. Yet, certain cancers have an affinity for specific tissues that are not anatomically convenient, such as prostate cancer spreading to bone and ocular melanoma metastasizing to the liver[3]. Adhesion molecule expression seems likely to influence this tissue-specific homing of metastases. However, these mechanisms may be attenuated in highly aggressive, undifferentiated tumors that display a more random distribution of metastases.

CLINICAL FEATURES

The clinical characteristics of cutaneous metastasis can provide important clues. When a patient with a known history of cancer presents with an extremely firm and rapidly growing erythematous nodule or an eruption of multiple skin nodules in close proximity to the primary tumor (Table 122.2), the diagnosis of cutaneous metastasis is relatively straightforward. However, the skin lesions may grow more slowly, and while metastases typically appear within several years of the diagnosis of the primary malignancy, they can present decades later.

The color of cutaneous metastases varies, from skin-colored to pink–red to blue–black, with the latter most commonly observed in metastatic melanoma (Fig. 122.3). In general, dermal and subcutaneous metastases are firmer on palpation than lipomas or epidermoid and tricholemmal (pilar) cysts. Cutaneous metastases can arise from hematogenous or lymphatic spread as well as direct extension. In the case of the latter two scenarios, as stated previously, proximity of the

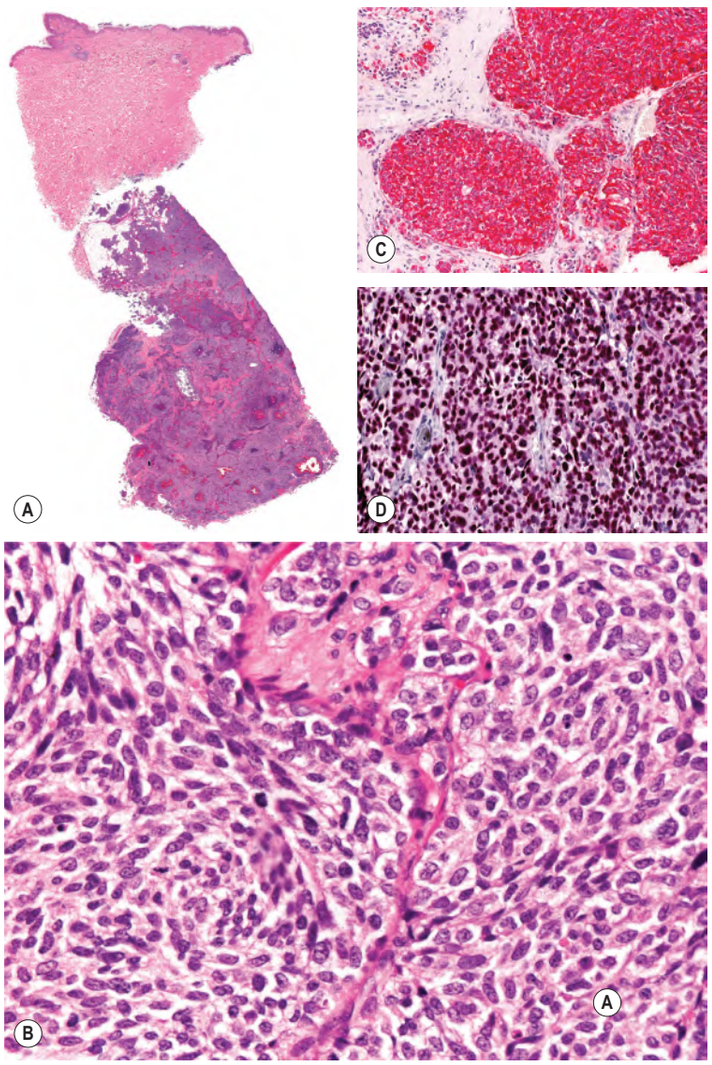

Fig. 122.2 Subcutaneous metastasis of small cell lung carcinoma. A Note sparing of the dermis. **B** Higher magnification demonstrating clusters of basaloid cells. **C** The tumor cells stain positively for CK7. **D** The tumor cells also stain positively for TTF-1 (thyroid transcription factor-1). *Courtesy Lorenzo Cerroni, MD.*

ANATOMIC LOCATIONS OF CUTANEOUS METASTASES			
Anatomic site	**Primary malignancy (men)**	**Primary malignancy (women)**	**Comments**
Scalp	Lung, renal	Breast	Can lead to alopecia ("alopecia neoplastica"; Fig. 122.3A)
Head & neck	SCC of the head & neck*, lung	Breast	Eyelid metastases from breast carcinoma have been reported; breast & lung metastases can lead to a "clown nose"
Upper extremities	Lung, renal, colon	Breast	Uncommon site in men and usually occurs late during disease
Back	Lung	Breast	20% of BSA, but site of 8% of metastases
Chest	Lung	Breast	
Abdomen	Colon, lung, stomach	Colon, ovary, breast	Sister Mary Joseph nodule (Fig. 122.4): most commonly gastric, colon, ovarian, or pancreatic cancers
Pelvis	Colon	Colon, ovary	Site of 8% of cutaneous metastases
Lower extremities	Melanoma > lung, renal	Melanoma > lung, renal	Uncommon site: 36% of BSA but site of only 4% of metastases

*e.g. larynx, oropharynx, nasal sinuses.

Table 122.2 Anatomic locations of cutaneous metastases. The trunk is the most common site (~55% of metastases) and the scalp is the site of ~15% of metastases[1]. BSA, body surface area; SCC, squamous cell carcinoma.
Adapted from Klein CA. Parallel progression of primary tumours and metastases. Nat Rev Cancer 2009;9:302–12.

Downloaded for Anonymous User (n/a) at Egyptian Knowledge Bank from ClinicalKey.com by Elsevier on March 10, 2024. For personal use only. No other uses without permission. Copyright ©2024. Elsevier Inc. All rights reserved.

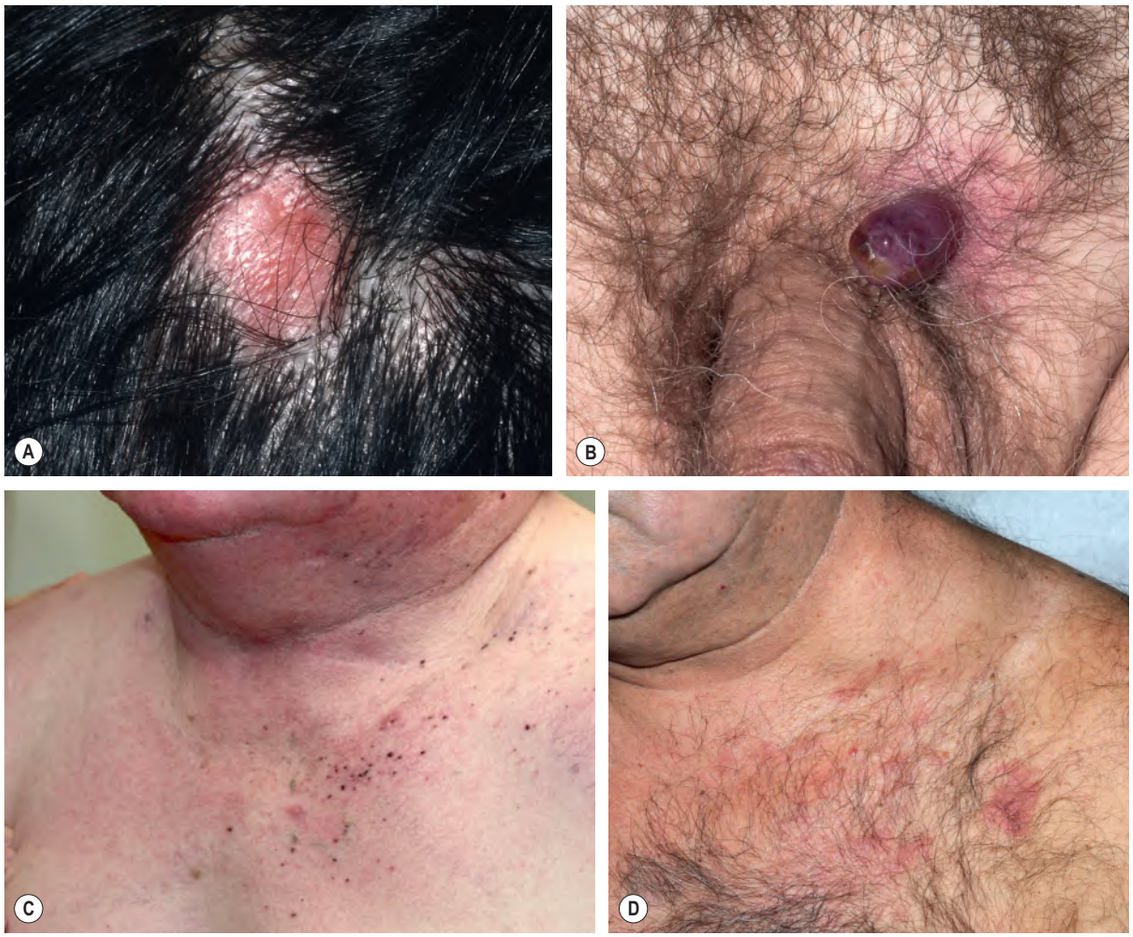

Fig. 122.3 Cutaneous metastases. A Pink nodule on the scalp with associated alopecia due to a metastasis from lung carcinoma (alopecia neoplastica). **B** Red–purple eroded nodule due to a metastasis from renal cell carcinoma; such lesions may be confused with vascular tumors. **C** Multiple small dark purple to black papules on the left neck and chest due to metastatic melanoma. **D** Pink papules and plaques on the chest due to metastases from adenocarcinoma of the colon. The patient was referred for treatment of dermatitis. *A, Courtesy Lorenzo Cerroni, MD; B, Courtesy Edward Cowen, MD; C, Courtesy Chris Bunick, MD; D, Courtesy Kalman Watsky, MD.*

Fig. 122.4 Cutaneous metastasis of colon carcinoma. An umbilical Sister Mary Joseph nodule presenting as a pink plaque with scale-crust. *Courtesy Stuart Lessin, MD.*

metastasis to the primary malignancy serves as a diagnostic clue. An example of lymphatic spread is in-transit metastases of melanoma while direct extension is most commonly observed with breast carcinoma and squamous cell carcinoma of the head and neck.

There are additional examples of anatomic localization, including the predilection of gastrointestinal malignancies to metastasize to the periumbilical region, referred to as a Sister Mary Joseph nodule (Fig. 122.4). Occasionally, implantation of tumor occurs at the time of a surgical procedure, e.g. chest tube placement for a malignant pleural effusion due to lung cancer. Although the distribution of cutaneous metastases is usually more random in the case of hematogenous spread, the scalp can be a preferred site for some malignancies, e.g. renal cell carcinoma.

Of all the carcinomas that metastasize to the skin, breast cancer may be the one with the widest range of clinical presentations (Table 122.3), varying from papulonodules to patches of erythema mimicking erysipelas (inflammatory carcinoma) to woody induration with a *peau d'orange* appearance (Fig. 122.5). The latter is often referred to as "*en cuirasse*" due to its clinical resemblance to the leather armor of a soldier (*cuirassier*)[1]. In addition, intravascular metastases can lead to erythematous papules that may resemble vascular proliferations, including the angiosarcomas that can follow breast irradiation (see Ch. 114).

Less common presentations include the dermatitis-like appearance of Paget disease, both mammary and extramammary (see Table 122.3). Metastases of renal cell carcinoma can resemble pyogenic granulomas, including a tendency to bleed (see Fig. 122.3B). Rarely, intravascular metastases lead to a reticulated vascular pattern that is reflective of a vaso-occlusive process or the cutaneous metastases assume an unusual distribution pattern, e.g. zosteriform.

In addition to metastases from solid organs, leukemias and systemic lymphomas can also involve the skin (see Chs. 119–121). The lesions are often pink–violet to red–brown papulonodules and therefore may be clinically indistinguishable from cutaneous metastases due to solid organ malignancies. Skin involvement by leukemia or lymphoma is classically not referred to as "metastases".

PATHOLOGY

Adenocarcinoma, squamous cell carcinoma (SCC), and melanoma represent the three major categories of cutaneous metastases (Table 122.4). In broad terms, these metastatic tumors generally lack an epidermal connection or involvement, are situated in the dermis or subcutis, and are composed of nodules, nests, or cords of atypical cells with mitoses (Table 122.5). However, it is important to note that occasionally there are primary "dermal" nodular melanomas[9], and primary cutaneous spindle cell SCCs often lack a prominent epidermal component. In addition, cutaneous metastases of both melanoma and

Downloaded for Anonymous User (n/a) at Egyptian Knowledge Bank from ClinicalKey.com by Elsevier on March 10, 2024. For personal use only. No other uses without permission. Copyright ©2024. Elsevier Inc. All rights reserved.

Fig. 122.5 Various presentations of cutaneous metastases of breast carcinoma. A Eroded erythematous nodules in the axilla. **B** Inflammatory form (carcinoma erysipeloides) with patches of erythema that may initially be misdiagnosed as infectious cellulitis. **C** Primarily *en cuirasse* form with obvious induration and *peau d'orange* appearance in addition to papulonodules. **D** Mixed pattern – reticulated erythema of carcinoma erysipeloides as well as *peau d'orange* appearance near the areola. *A, D, Courtesy Stuart Lessin, MD.*

CLINICAL PRESENTATIONS OF CUTANEOUS METASTASES AND HISTOLOGIC CORRELATES			
Type	**Clinical description**	**Histology**	**Associated primary malignancy**
Dermal or subcutaneous nodules	Small miliary lesions to large tumors; single or multiple	Tumor cells infiltrating among collagen bundles or replacing dermis; grenz zone often present	Most common presentation; any type
Inflammatory carcinoma (carcinoma erysipeloides)	Erythematous patch with spreading border; resembles erysipelas	Tumor cells within dilated lymphatic vessels	Breast ≫ lung, ovary, prostate, GI, others
En cuirasse	Morpheaform or sclerodermoid, depending upon extent; indurated with *peau d'orange* appearance	Fibrosis with infiltrating tumor cells	Breast ≫ lung, GI, kidney, others
Carcinoma telangiectodes	Red–violet papules; purpuric patches with telangiectasias	Tumor cells within superficial blood vessels and RBC sludging	Breast
Paget disease*	Patches extending from the nipple and areola that resemble dermatitis	Large, atypical epithelial cells with abundant pale cytoplasm arranged in solitary units and small nests within all layers of the epidermis	Breast
Alopecia neoplastica	Nodules or plaques on the scalp in association with alopecia	Cords of tumor cells between collagen bundles	Breast > lung (Fig. 122.3A), renal, others
Pyogenic granuloma-like	Rapidly growing nodule resembling a vascular tumor (particularly a pyogenic granuloma)	Neoplastic cells in cords and lobules admixed with prominent hemorrhage and "pseudovascular" spaces	Renal clear cell carcinoma (Fig. 122.3B), hepatocellular carcinoma > others

*Lesions of extramammary Paget disease share similar histopathologic features with those of Paget disease of the breast, but usually represent (>75% of patients) primary cutaneous adenocarcinomas (see Ch. 73); an underlying visceral malignancy is most likely when there is perianal involvement.

Table 122.3 Clinical presentations of cutaneous metastases and histologic correlates. An individual patient can have an admixture of the various types. Occasionally, cutaneous metastases have a zosteriform distribution pattern and clinically they can resemble dermatoses, including eczema, vasculitis, and erythema annulare centrifugum. Obviously, they can also mimic cutaneous tumors, including non-melanoma skin cancers, epidermoid or pilar cysts, lipomas, granular cell tumors, or angiosarcoma[4]. GI, gastrointestinal; RBC, red blood cell.

Downloaded for Anonymous User (n/a) at Egyptian Knowledge Bank from ClinicalKey.com by Elsevier on March 10, 2024. For personal use only. No other uses without permission. Copyright ©2024. Elsevier Inc. All rights reserved.

PATHOLOGIC FINDINGS IN CUTANEOUS METASTASES			
Malignancy	**Possible histological clues**	**Immunohistochemical markers**	**Comments**
Adenocarcinomas – CEA positive and typically negative for p40/p63, CK5/6, D2–40 (podoplanin)			
Breast	Single filing or cords of cells (lobular CA); tumor cells form glandular structures (ductal CA); signet ring cells	CK7, ER/PR, mammoglobulin, gross cystic disease fluid protein-15 (GCDFP-15), GATA3	Breast CA can be ER/PR-negative; GCDFP-15 positivity also seen in cutaneous adnexal and salivary gland tumors; occasionally, ER/PR positivity in some primary cutaneous adnexal carcinomas
Colon	Columnar cells with basally oriented nuclei and intracytoplasmic mucin production; gland formation; "dirty" necrosis	CK20, CDX2, villin, SATB2	Mucinous CA can develop from other tissues (lung, ovary, uterine cervix) and rarely can be primary cutaneous
Non-small cell lung, adenocarcinoma		CK7, TTF-1, napsin A	Non-small cell lung CA can be TTF-1-negative; TTF-1 positivity not limited to lung or thyroid CA
Ovarian	Psammoma bodies can be seen in papillary serous CA	CA125, CK7, ER/PR, mesothelin, WT-1 (serous CA), PAX8	Mucinous ovarian CA may closely resemble other types of mucinous CA
Prostate		PSA, PSAP, NKX3.1	High-grade CA may lose glandular differentiation as well as PSA & PSAP expression
Pancreatobiliary		CK7, CK20, CA19.9, CA125	CA19.9 is not specific for pancreatobiliary tumors
Gastric	Signet ring cells (signet ring type)	CK7, CK20, lysozyme, CDX2, CDH17	Non-signet ring cell type gastric CA may not have distinct morphology; signet ring cell CA is not limited to the stomach (e.g. can be seen in breast CA)
Thyroid	Thyroid follicle formation (follicular CA); papillary structure, psammoma bodies (papillary CA)	TTF-1, thyroglobulin, napsin A	High-grade tumors (insular CA, anaplastic CA) may lose characteristic thyroid gland morphology
Squamous cell carcinoma – islands of keratin-producing epithelial cells that stain positively for cytokeratins (e.g. CK5/6, CK903, MNF116) and p40/p63			
Melanoma – stains positively for S100, SOX10, HMB45, MITF, MelanA (MART-1); see Ch. 113			
Merkel cell carcinoma – stains positively for CK20, SATB, and in a majority of cases, Merkel cell polyomavirus; see Ch. 115			
Neuroendocrine (non-Merkel cell carcinoma)			
Small cell carcinoma (including lung)	Nuclear molding, scant cytoplasm, indistinct nucleoli	Keratins, INSM1, TTF-1, CD56, neuron-specific enolase, chromogranin, synaptophysin; negative for CK20	Some small cell CAs, including lung, may not express neuroendocrine markers
Neuroendocrine tumor, including carcinoid tumor and atypical carcinoid tumor	Nests of cells with neuroendocrine morphology	Neuroendocrine markers (INSM1, CD56, chromogranin); medullary thyroid CA: calcitonin and TTF-1	Poorly preserved tissue may resemble lymphoma, carcinoma or small cell CA
Other			
Renal (clear cell)	Clear cytoplasm, highly vascular	Co-expression of EMA and vimentin, PAX8, CD10, RCC-Ma, napsin A	Renal cell CA can be composed of other cell types (e.g. granular or spindle)
Bladder and urothelial	Medium-sized tumor cells arranged in nests or sheets	p40/p63, CK5/6, CK7, CK20, GATA3; uroplakin II	May resemble high-grade cutaneous adnexal CA

Table 122.4 Pathologic findings in cutaneous metastases. p40/p63 negativity favors metastases, but it may be negative in some cutaneous adnexal carcinomas, particularly mucinous eccrine carcinoma. CA, carcinoma; CDH17, cadherin 17; CDX2, homeobox protein CDX2; CEA, carcinoembryonic antigen; CK, cytokeratin; EMA, epithelial membrane antigen; ER, estrogen receptor; GATA3, a transcription factor that regulates mammary epithelial differentiation; INSM1, insulinoma-associated protein 1; MITF, microphthalmia transcription factor; MNF116, pankeratin marker; NKX3.1, NK3 homeobox 1; PAX8, paired box 8; PR, progesterone receptor; PSA, prostate-specific antigen; PSAP, prostatic-specific acid phosphatase; RCC-Ma, renal cell carcinoma marker – detects a renal tubule antigen (highly specific); SATB2, special AT-rich sequence-binding protein 2/SATB homeobox 2; SCC, squamous cell carcinoma; SOX-10, SRY-box transcription factor 10; TTF-1, thyroid transcription factor 1; WT-1, product of Wilms tumor gene.

HISTOLOGIC CLUES TO THE DIAGNOSIS OF CUTANEOUS METASTASES
Well-circumscribed, usually symmetric, dermal or subcutaneous nodules of atypical cells with numerous mitoses and without connection to the epidermis (rarely cutaneous metastases are epidermotropic)
Presence of atypical cells within lymphatic vessels (differential diagnosis: intravascular lymphoma [neoplastic cells found in blood, not lymphatic, vessels], intravascular angiosarcoma [neoplastic cells in blood or lymphatic vessels], intralymphatic histiocytosis, intralymphatic cutaneous anaplastic large cell lymphoma, benign intralymphatic proliferation of T cell lymphoid blasts, Merkel cell carcinoma [neoplastic cells usually in lymphatic vessels, rarely in blood vessels])
Atypical cells arranged in lines within the dermis (differential diagnosis: myelogenous leukemia)
Presence of necrosis *en masse* at the center of a nodule of atypical cells (differential diagnosis: some lymphomas, some primary cutaneous adnexal carcinomas)

Table 122.5 Histologic clues to the diagnosis of cutaneous metastases.

SCC (cutaneous, oropharyngeal, or solid organ) may show significant epidermal involvement so that distinction from a synchronous or metachronous primary skin tumor can be difficult. Four primary histopathologic patterns of cutaneous metastases are: (1) nodular; (2) diffuse, including infiltrative; (3) intravascular, including intralymphatic; and (4) epidermotropic (Fig. 122.6).

The following can serve as histologic clues to the diagnosis of cutaneous metastases, in addition to those outlined in Table 122.5: (1) atypical single cells infiltrating through collagen bundles (breast carcinoma[10]; see Fig. 122.6B); (2) clear cells plus abundant hemorrhage (renal cell carcinoma; Fig. 122.7); (3) "dirty" necrosis within glandular structures (colon carcinoma); (4) formation of colloid within

Downloaded for Anonymous User (n/a) at Egyptian Knowledge Bank from ClinicalKey.com by Elsevier on March 10, 2024. For personal use only. No other uses without permission. Copyright ©2024. Elsevier Inc. All rights reserved.

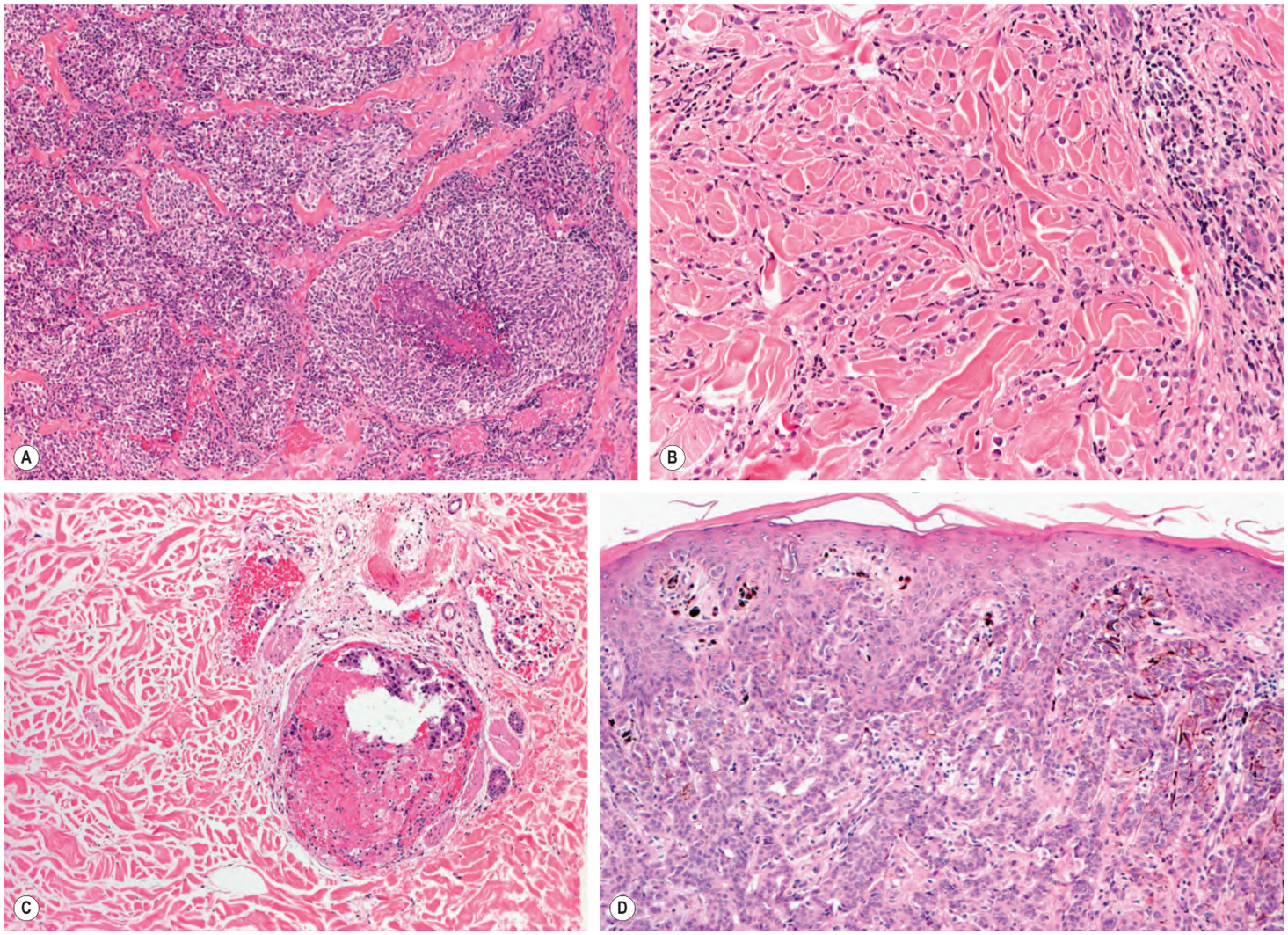

Fig. 122.6 Major patterns of cutaneous metastases. A Nodular pattern with focal, prominent necrosis in a cutaneous metastasis of small cell lung carcinoma. **B** Diffuse pattern with linear arrays of single cells in a metastasis of breast carcinoma. **C** Intralymphatic pattern in a metastatic breast carcinoma; tumor cells are confined to dilated lymphatic vessels. **D** Epidermotropic pattern in a metastasis of breast carcinoma; tumor cells are in both the dermis and the epidermis. The presence of focal pigmentation and melanocyte hyperplasia could lead to the misdiagnosis of a melanocytic tumor. *Courtesy Lorenzo Cerroni, MD.*

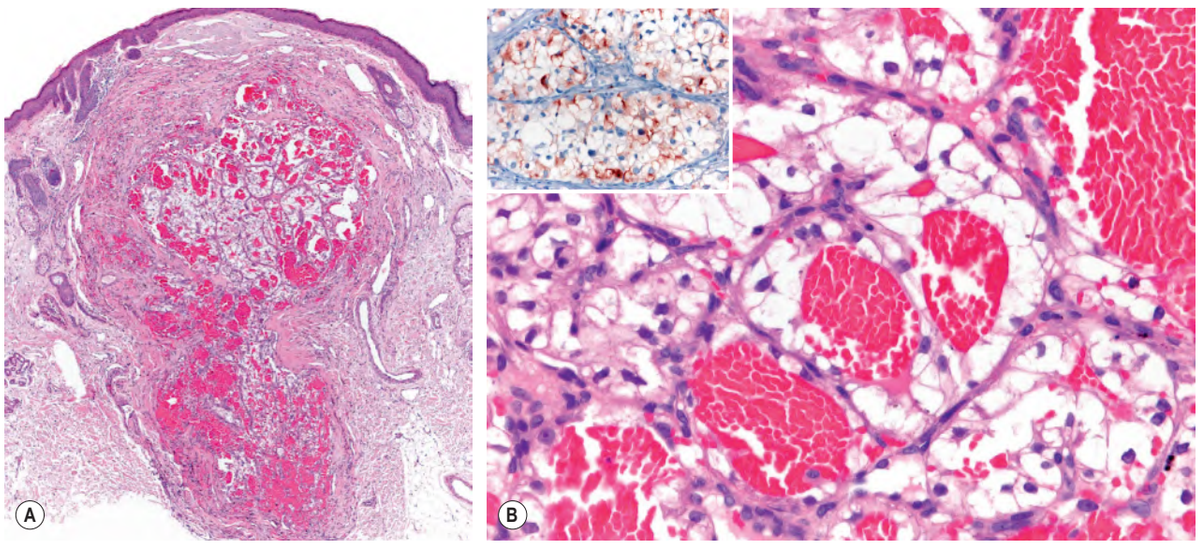

Fig. 122.7 Histopathologic features of cutaneous metastasis from clear cell renal cell carcinoma. A Vertically oriented hemorrhagic tumor within the dermis resembling an angiomatous tumor. **B** Tumor cells with clear cytoplasm arranged as fine trabecular structures and lobules surrounding hemorrhagic areas. The lack of prominent atypia can be misleading and lead to the erroneous diagnosis of hemangioma. Positive immunohistochemical staining with RCC-Ma (renal cell carcinoma marker), a monoclonal antibody directed against a proximal tubule antigen, labels clear cell renal cell carcinoma (inset). *Courtesy Lorenzo Cerroni, MD.*

Downloaded for Anonymous User (n/a) at Egyptian Knowledge Bank from ClinicalKey.com by Elsevier on March 10, 2024. For personal use only. No other uses without permission. Copyright ©2024. Elsevier Inc. All rights reserved.

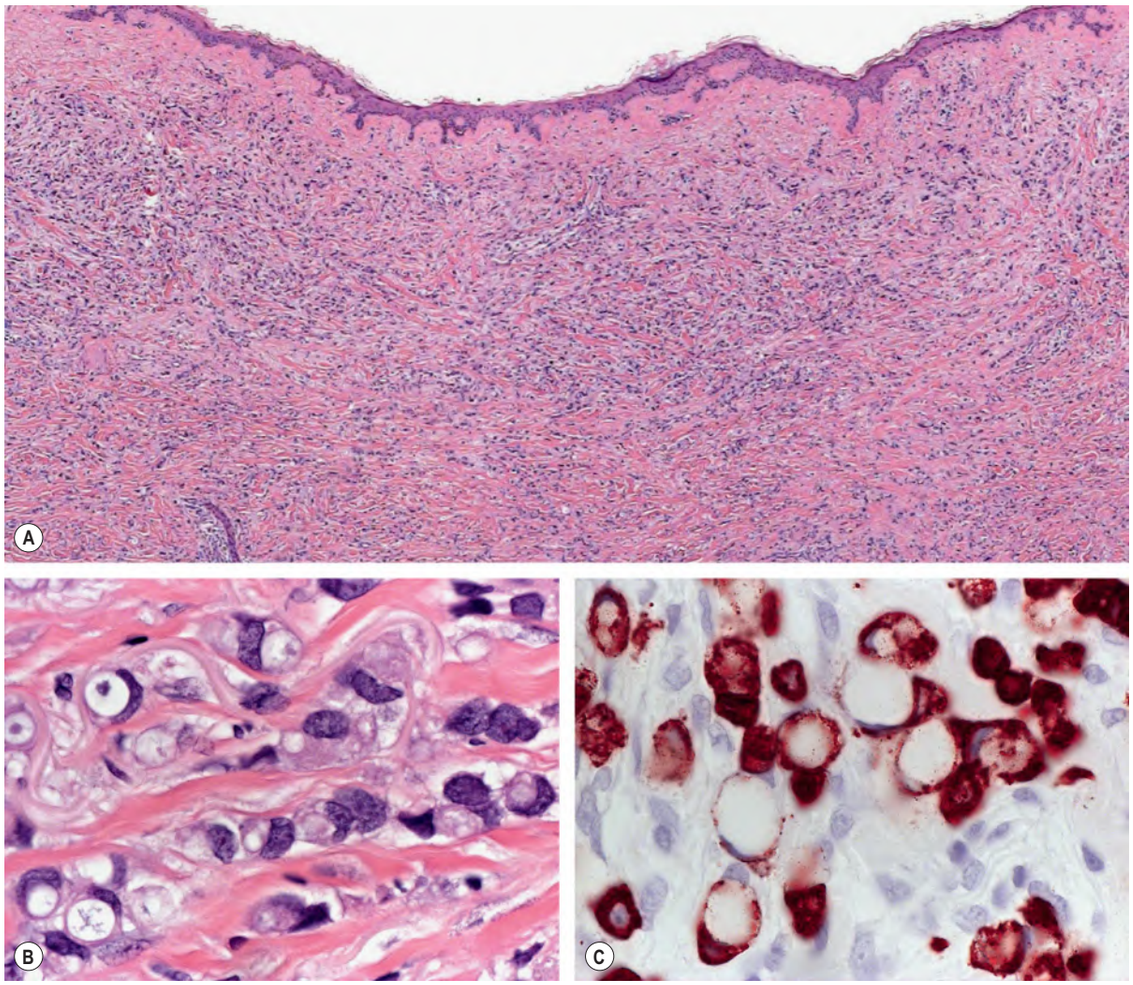

Fig. 122.8 Histopathologic features of cutaneous metastases of signet ring adenocarcinoma of the breast (A, B) and stomach (C). A Diffuse infiltration of neoplastic cells throughout the entire dermis. **B** Detail of neoplastic cells with signet ring cell morphology due to intracellular mucin accumulation. **C** Signet ring cells are not unique to breast carcinoma and may be observed in primary cutaneous carcinomas (e.g. histiocytoid carcinoma of the eyelid), non-epithelial neoplasms (e.g. melanoma), and a variety of adenocarcinomas, particularly those from the gastrointestinal tract. A cytokeratin (pan-CK) stain in this metastatic signet ring cell carcinoma of the stomach highlights the peculiar morphology of the cells, with intracellular mucin pressing the nuclei and distorting them, thus conferring the characteristic shape similar to that of a signet ring. *Courtesy Lorenzo Cerroni, MD.*

lumina (thyroid carcinoma); (5) psammoma bodies (thyroid or ovarian carcinoma); and (6) signet ring cells (gastric or breast carcinoma; Fig. 122.8)[11]. In addition to melanoma and SCC (see above), epidermotropism can occasionally be seen in cutaneous metastases from other malignancies, in particular breast carcinoma, and less often carcinomas of the prostate, colon, larynx, penis, or vagina[11]. Rarely, epidermotropic metastases, especially from breast carcinoma, may contain pigment and even an intratumoral increase in melanocytes, leading to the misdiagnosis of a melanocytic tumor (see Fig. 122.6D). When there is intravascular involvement, this may be confused with benign entities such as intralymphatic histiocytosis (Fig. 122.9).

Complete evaluation of a cutaneous metastasis often requires the use of a panel of histochemical stains (Fig. 122.10; see Table 122.4)[12]. While such stains are not a substitute for a detailed history and physical examination plus diagnostic imaging and biopsy of the primary tumor[12], the resulting information does provide direction and may circumvent the need for a more invasive biopsy of another tissue. In order to distinguish between a primary cutaneous tumor (usually an adnexal carcinoma) and a cutaneous metastasis (especially of adenocarcinoma), immunostains, in particular p40/p63, CK5/6 and D2–40 (podoplanin), can prove helpful[13–15]. Primary cutaneous tumors are typically positive for some or all these markers and metastases lack staining. Important exceptions are p63-positivity in some metastatic adenocarcinomas (breast, urothelial, and lung) and an absence of p63 staining in some primary cutaneous adnexal carcinomas.

In the case of cutaneous metastases from adenocarcinomas, various combinations of CK7 and CK20 expression can provide useful information (see Fig. 122.10)[15]. This panel is also employed to evaluate extramammary Paget disease, in which CK20 positivity points to a secondary form of the disease that is originating from a visceral malignancy (see Fig. 73.16).

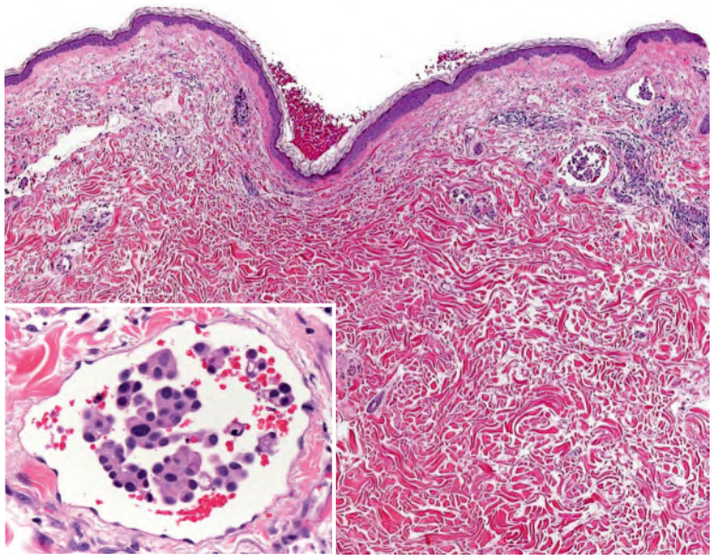

Fig. 122.9 Histopathologic features of cutaneous metastasis of urothelial micropapillary bladder carcinoma. Complexes of neoplastic cells within dilated lymphatic spaces in the dermis. Detail of a lymphatic space with intravascular tumor complexes admixed with erythrocytes (inset). Neoplastic urothelial (transitional) cells exhibit round–ovoid nuclei and abundant eosinophilic cytoplasm, and they form small rosette-like aggregates. These histopathologic features may simulate a benign condition, namely, intralymphatic histiocytosis. *Courtesy Lorenzo Cerroni, MD.*

Downloaded for Anonymous User (n/a) at Egyptian Knowledge Bank from ClinicalKey.com by Elsevier on March 10, 2024. For personal use only. No other uses without permission. Copyright ©2024. Elsevier Inc. All rights reserved.

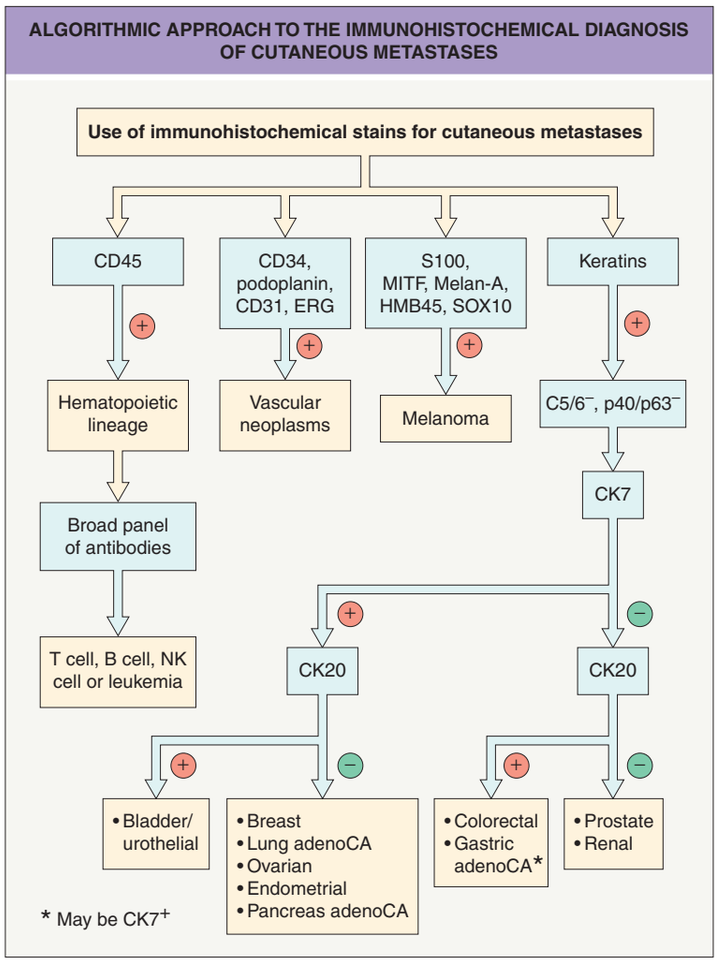

Fig. 122.10 Algorithmic approach to the immunohistochemical diagnosis of cutaneous metastases. The main differential diagnosis of metastatic adenocarcinoma is a primary cutaneous adnexal tumor (generally CK5/6$^+$, p40$^+$/p63$^+$). For tumors not clearly classifiable as a primary skin tumor, clinical history and directed immunohistochemical stains can be key to confirming the diagnosis. adenoCA, adenocarcinoma. *Adapted from Handa U, Kundu R, Dimri K. Cutaneous metastasis: a study of 138 cases diagnosed by fine-needle aspiration cytology. Acta Cytol 2017;61:47–54; Saeed S, Keehn CA, Morgan MB. Cutaneous metastasis: a clinical, pathological, and immunohistochemical appraisal. J Cutan Pathol 2004;31:419–30.*

Certain organ-restricted markers may also be useful including: CD10, RCC, and PAX8 (positive in renal and ovarian tumors); thyroid-specific transcription factor-1 (TTF-1) (thyroid, lung; see Fig. 122.2); thyroglobulin (thyroid); prostate specific antigen (PSA) and NKX3.1 (prostate); CDX2, CDH17, and SATB2 (gastrointestinal); Hep Par1 and arginase-1 (hepatocellular carcinoma); and CD56 and insulinoma-associated protein 1 (INSM1) (neuroendocrine) (see Table 122.4). In cutaneous metastases of SCC, staining for pankeratins and EMA may be positive, but this information is not helpful in determining the site of the primary SCC.

In addition to the histologic examination of conventional skin biopsies, cutaneous metastases can be sampled via fine-needle aspiration cytology[16].

TREATMENT AND PROGNOSIS

Typically, cutaneous metastases are a harbinger of late-stage or progressive disease and as such portend a poor prognosis. The average survival time following the initial diagnosis of cutaneous metastasis is 7.5 months[17] and half of patients expire within the first 6 months[18]. Whether the patient has a known or unknown primary malignancy, the development of cutaneous metastases calls for a multidisciplinary approach, including medical and surgical oncologists, radiation oncologists, and mental health care providers when appropriate. Localized treatment of cutaneous metastases can be undertaken for functional, palliative, or cosmetic indications. When feasible, surgical excision is performed; however, radiation and focal chemotherapeutics or immunotherapies can be considered on a case-by-case basis. Systemic therapies are indicated for immuno- or chemotherapy-responsive tumors. When malodorous, topical metronidazole solution (supplied for intravenous use) can be applied via cotton gauze or pump spray once to twice daily or crushed metronidazole tablets can be sprinkled onto the tumor twice daily.

Additional figures available in our eBook (see inside front cover for access code).

REFERENCES

1. Lookingbill DP, Spangler N, Helm KF. Cutaneous metastases in patients with metastatic carcinoma: a retrospective study of 4020 patients. *J Am Acad Dermatol*. 1993;29:228–236.
2. Nashan D, Lucas Muller M, Braun-Falco M, et al. Cutaneous metastases of visceral tumors: a review. *J Cancer Res Clin Oncol*. 2009;135:1–14.
3. Schwartz RA. Cutaneous metastatic disease. *J Am Acad Dermatol*. 1995;33:161–182.
4. Sariya D, Ruth K, Adams-McDonnell R, et al. Clinicopathologic correlation of cutaneous metastases: experience from a cancer center. *Arch Dermatol*. 2008;144:1155–1162.
5. Brodland DG, Zitelli JA. Mechanisms of metastasis. *J Am Acad Dermatol*. 1992;27:1–10.
6. Brodland DG. The life of a skin cancer. *Mayo Clin Proc*. 1997;72:475–478.
7. Morgan-Parkes JH. Metastases: mechanisms, pathways, and cascades. *Adv Clin Med*. 1995;164:1075–1082.
8. Klein CA. Parallel progression of primary tumours and metastases. *Nat Rev Cancer*. 2009;9:302–312.
9. Swetter SM, Ecker PM, Johnson DL, Harvell JD. Primary dermal melanoma. A distinct subtype of melanoma. *Arch Dermatol*. 2004;140:99–103.
10. McKee PH. Cutaneous metastases. *J Cutan Pathol*. 1985;12:239–250.
11. Schwartz RA. Histopathologic aspects of cutaneous metastatic disease. *J Am Acad Dermatol*. 1995;33:649–657.
12. Bellizzi AM. An algorithmic immunohistochemical approach to define tumor type and assign site of origin. *Adv Anat Pathol*. 2020;27:114–163.
13. Mahalingam M, Nguyen LP, Richards JE, et al. The diagnostic utility of immunohistochemistry in distinguishing primary skin adnexal carcinomas from metastatic adenocarcinom to skin: an immunohistochemical reappraisal using cytokeratin 15, nestin, p63, D2-40, and calretinin. *Mod Pathol*. 2010;23:713–719.
14. Lee JJ, Mochel MC, Piris A, et al. p40 exhibits better specificity than p63 in distinguishing primary skin adnexal carcinomas from cutaneous metastases. *Hum Pathol*. 2014;45:1078–1083.
15. Chu P, Wu E, Weiss LM. Cytokeratin 7 and cytokeratin 20 expression in epithelial neoplasms: a survey of 435 cases. *Mod Pathol*. 2000;13:962–972.
16. Handa U, Kundu R, Dimri K. Cutaneous metastasis: a study of 138 cases diagnosed by fine-needle aspiration cytology. *Acta Cytol*. 2017;61:47–54.
17. Saeed S, Keehn CA, Morgan MB. Cutaneous metastasis: a clinical, pathological, and immunohistochemical appraisal. *J Cutan Pathol*. 2004;31:419–430.
18. Schoenlaub P, Sarraux A, Grosshans E, et al. Survival after cutaneous metastasis: a study of 200 cases. *Ann Dermatol Venereol*. 2001;128:1310–1315.

Downloaded for Anonymous User (n/a) at Egyptian Knowledge Bank from ClinicalKey.com by Elsevier on March 10, 2024. For personal use only. No other uses without permission. Copyright ©2024. Elsevier Inc. All rights reserved.

eFig. 122.1 Melanoma metastases. Cluster of firm blue and skin-colored nodules in the axilla.

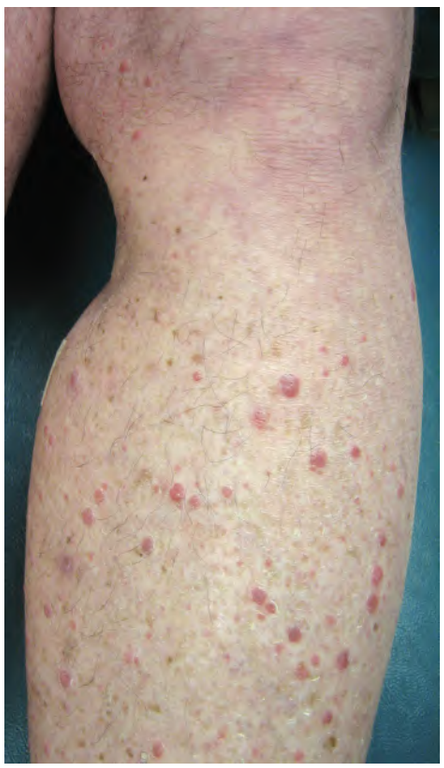

eFig. 122.2 Metastases of melanoma. Multiple pink firm papules on the leg.

eFig. 122.3 Metastasis of renal cell carcinoma (alopecia neoplastica). The scalp is a preferred site for cutaneous metastases of renal cell carcinoma.

eFig. 122.4 Metastasis of signet ring adenocarcinoma (alopecia neoplastica). A firm lobulated pink plaque on the scalp. *Courtesy Nour Kibbi, MD.*

eFig. 122.5 Scalp metastases of breast carcinoma. Note the lack of terminal hairs within the pink plaques. *Courtesy Jonathan Leventhal, MD.*

Downloaded for Anonymous User (n/a) at Egyptian Knowledge Bank from ClinicalKey.com by Elsevier on March 10, 2024. For personal use only. No other uses without permission. Copyright ©2024. Elsevier Inc. All rights reserved.

eFig. 122.6 Metastasis of renal cell carcinoma. Pink–violet firm papule with telangiectasias on the scalp. *Courtesy Jonathan Leventhal, MD.*

eFig. 122.8 Metastasis of signet ring adenocarcinoma (unknown primary). Firm pink plaque with telangiectasias on the chest. *Courtesy Nour Kibbi, MD.*

eFig. 122.7 Multiple metastases of colon carcinoma along the surgical excision scar. *Courtesy Jonathan Leventhal, MD.*

eFig. 122.9 Metastasis of breast carcinoma. The large, ulcerated, red–purple nodule was very firm to palpation. *Courtesy Jeffrey M. Cohen, MD.*

Downloaded for Anonymous User (n/a) at Egyptian Knowledge Bank from ClinicalKey.com by Elsevier on March 10, 2024. For personal use only. No other uses without permission. Copyright ©2024. Elsevier Inc. All rights reserved.